

Systematic Review

Value of MRI in the cervical spine imaging series of trauma patients: A state-of-the-art review



S.R. Sarblah ^{a, b}, P. Rachman ^b, W.K. Antwi ^c, M.N.K. Anudjo ^{d, e}, B.O. Botwe ^{c, f},
T.N. Akudjedu ^{d, *}

^a Radiology Department, Hereford County Hospital, Wye Valley NHS Foundation Trust, Hereford, UK

^b Department of Health Sciences, Faculty of Environmental & Life Sciences, Southampton University, UK

^c Department of Radiography, School of Biomedical and Allied Health Sciences, College of Health Sciences, University of Ghana, Box KB143, Korle Bu, Accra, Ghana

^d Institute of Medical Imaging & Visualisation, Department of Medical Science & Public Health, Faculty of Health & Social Sciences, Bournemouth University, Bournemouth, UK

^e School of Radiology, AECC University College, Bournemouth, UK

^f Department of Midwifery and Radiography Division School of Health & Psychological Sciences, City, University of London, Northampton Square, London EC1V 0HB, UK

ARTICLE INFO

Article history:

Received 19 December 2023

Received in revised form

5 April 2024

Accepted 18 April 2024

Keywords:

Trauma

Cervical spine injuries

Magnetic resonance imaging

Computed tomography

ABSTRACT

Introduction: Clinical decision protocols for evaluation and assessment of traumatic cervical spine injuries (TCSI) lean more towards the use of CT imaging. Investigation with MRI is therefore considered unnecessary following negative CT findings according to some local protocols. This review aims to explore what benefits MRI may offer in the clinical management of TCSI patients.

Methods: A systematic search of the literature was conducted in the following databases: AMED, CINAHL, EMBASE and MEDLINE using defined key terms and synonyms optimised for each database. The eligible articles were subjected to data extraction and thematic synthesis.

Results: The initial electronic search yielded 2527 articles. Of these, 15 articles remained following the application of a pre-defined inclusion criteria and full-text assessment. Four themes (mechanism of injury, type of patient, injuries detected on MRI, significance of injuries detected on MRI) were developed relating to the usage and value of MRI in the management of TCSI.

Discussion: Our findings indicate that MRI may be very valuable in some situations for the evaluation of TCSI, however, its usage must be cautiously considered on a case-by-case basis in light of additional clinical benefit, patient safety and resource availability following a normal CT scan or in conjunction with CT or projection radiography where appropriate.

Implications for practice: MRI may serve as a confirmatory test in the management pathway of TCSI based on individual clinical needs. Consideration for key limitations (e.g., patients' cooperation) and accessibility challenges (e.g., cost) against the clinical benefit to the patient must be noted. Development of centre-specific policies from standard trauma imaging protocols may be essential for the timely management of TCSI.

© 2024 The Author(s). Published by Elsevier Ltd on behalf of The College of Radiographers. This is an open access article under the CC BY license (<http://creativecommons.org/licenses/by/4.0/>).

Introduction

Trauma is associated with potential adverse consequences in all age groups worldwide.¹ In Western countries, physical trauma-related events are a part of the leading causes of death.² Traumatic cervical spine injuries (TCSI) are of clinical significance,³ and

thus, timely clinical assessment is critical for management.^{4,5} Missed injuries and diagnostic delays are some of the common problems in the treatment of polytrauma, resulting in significant morbidity, deformities, and, in some cases, death.⁶

Medical imaging is a vital diagnostic intervention in eliciting TCSI. Often, this relies on local and international clinical decision rules and guidelines such as the National Emergency X-Radiography Utilisation Study (NEXUS) (Australia), the Canadian C-spine rule⁷ and the National Institute of Care Excellence (NICE) guidelines⁸ (United Kingdom). Although each of these guidelines is based

* Corresponding author.

E-mail address: takudjedu@bournemouth.ac.uk (T.N. Akudjedu).

✉ (T.N. Akudjedu)

on evidence, the question of which is preferred remains debatable as each has key considerations for when imaging is necessary, and the specific imaging required. For instance, the Canadian C-spine rule suggests three high risk factors including: patients ≥ 65 yrs, dangerous mechanisms of trauma and sensory neurological deficits for which imaging is mandatory.⁷ Though evidence base does not exist for the combination of these guidelines for the clearance of TCSI, the Eastern Association for the Surgery of Trauma (EAST)⁹ and the British Trauma Society⁷ recommends the neck movement criterion which emanates from the Canadian C-spine rule and the NEXUS criteria.

CT may be optimal in delineating spinal fractures due to better bony resolutions; however, it is limited in demonstrating injuries encompassing the ligaments, tendons, spinal cord, blood vessels and nerve roots as compared to magnetic resonance imaging (MRI).^{18–22} Additionally, MRI is preferred for paediatrics as it does not involve ionising radiation, and is suitable for accurate and early detection of neurovascular anatomical TCSI and classification.^{23,24} While current TCSI imaging protocols^{9,10} recommend computed tomography (CT) scan as the first line of investigation for suspected cervical spine injuries (CSI), the Western Australian Department of Health, Diagnostic Imaging Pathways for Cervical Spine Injury¹¹ and the advanced trauma life support (ATLS) spine and Spinal Cord Trauma guideline recommends that CS radiograph alone is appropriate when sufficient projection radiographs are obtainable in patients at low risk (of developing complications) and a concurrent CT is not required. This is however not supported by a plethora of empirical evidence^{12–16} which shows that a significant proportion of CSI are missed on radiographs and therefore should only be used where CT is not available and high-quality projection radiographs are obtainable and preferably reported by qualified practitioners.¹⁷

Hodgson and colleagues²⁵ argued that in certain situations, to holistically rule out TCSI, use of a combination of MRI and CT may be critical, and this approach is supported by the NICE guideline.⁸ Specifically, the NICE guideline recommends MRI in the presence of abnormal neurological examination to exclude injuries to the C-spine disc, spinal cord, and ligaments following a prior positive or negative CT finding.

It remains unclear what the imaging pathway is for TCSI assessment in obtunded patients, thus, guidance around whether a CT scan alone gives enough diagnostic certainty or the need for further imaging with MRI is lacking.²⁶ This often arises due to unreliable physical examination and/or difficulty to assess the cervical spine among this cohort. However, availability and accessibility to further MRI imaging is challenged by financial constraints, and consequently a disproportionate distribution of MRI scanners in certain parts of the world.²⁷ James and colleagues²⁸ recommend the use of further imaging in settings with available MRI resources for detecting clinically significant injuries resulting from blunt trauma with normal CT findings. These issues, however, re-enforce the need for a multimodal (MRI/CT) imaging approach to TCSI assessment, especially in situations of negative CT findings.^{29–32} Of note, Craxford et al.³³ observed significant variations in current clinical management protocols for the assessment of TCSI in patients with multiple injuries in hospitals in England and thus, suggested the reliance on the experience of trauma networks for the design of standardised care plans for trauma patients. Platzer et al.³⁴ highlighted the need for a generally approved guideline for the assessment of CSI in polytrauma patients to reduce delays. This review aims to provide an update to similar previous works^{28,29}; explore what benefits MRI may offer in to the clinical management of TCSI patients to address the existing controversies and add to the evidence base informing a standardised imaging pathway for the management of CSI.

Methodology

A state-of-the-art review approach is considered appropriate for this study to provide an understanding of the current state of knowledge while highlighting priorities for future consideration.^{66,67} Briefly, this methodology adopts a comprehensive and structured approach of information gathering, evaluating, and synthesising (typically narrative) of existing relevant studies on a specific research question/topic. It aims to minimise bias and provide an objective summary of the available evidence by following a predefined set of methods and criteria. Typically, a formal quality assessment of studies is not required for state-of-the-art reviews,^{66,67} however, to minimise bias and to provide a good understanding of the evidence, this study employed a quality assessment.

Study approach & data sources

An electronic literature search approach was employed across multiple online databases including AMED, CINAHL, EMBASE and MEDLINE in accordance with the Cochrane Collaboration guide³⁵ together with the Preferred Reporting Items for Systematic Review (PRISMA) statement.³⁶ A manual search of Google Scholar and the reference list of relevant primary studies and review articles were also searched for other relevant publications that fulfil the eligibility criteria. Ethical approval is not required for literature reviews.

Eligibility criteria

The inclusion and exclusion criteria are detailed in [Table 1](#). Briefly, articles were included if they were published in English and explored the use of MRI and/or other cross-sectional imaging modalities in the evaluation of TCSI across varied demographic groups. Furthermore, it was ensured that the final articles adequately addressed each of the key elements of the PICO (Population, Intervention, Comparison, Outcome) framework³⁷ ([Table 2](#)). Opinion reports, preprints, commentaries, and literature reviews were excluded and primary studies which were conducted on spinal regions other than the c-spine were excluded.

Search strategy

The search strategy was developed in consultation with an expert librarian to identify studies in each of the databases. Keywords and synonyms were identified from the MeSH (Medical Subject Heading) for the literature search ([Table 3](#)). Briefly, the Boolean operators (OR, AND), and the identified keywords/MeSH terms and synonyms were used to develop phrase combinations for the search ([Table 3](#)). Of note, these search combinations were refined to include appropriate subject headings, abbreviations and/or truncated syntax in accordance with the specifications of each database to increase the sensitivity while minimising the risk of missing relevant articles. Using this search strategy, an independent initial electronic literature search was carried out by the first author (SRS) from April 2018 to July 2018 to identify relevant articles. A comprehensive search was conducted (November 2022 by SRS and TNA) and further updated in September 2023 by MNKA and TNA and conclude on the actual pieces of evidence that are relevant for the review. The screening processes and the search outputs were managed with Microsoft Excel 2019 for Mac and the RefWorks (ExLibris, ProQuest) referencing software.

Study selection, data extraction and synthesis

Following our predetermined search strategy, the potential articles found were first screened against the titles that appeared

Table 1
Inclusion and exclusion criteria.

Inclusion Criteria	Exclusion Criteria	Justification
English language literatures	Non – English literatures	This would ensure that the constraints and cost involved in translation is avoided This may however introduce bias because relevant text in other language would probably be missed.
Accessible full text literatures	Literatures without full text	To avoid the time constraints and possible delays that may be incurred while trying to obtain access to the full text from authors
2008 to 2022	Before 2008	To ensure that the evidence obtained are current and applicable to the current practices.
Trauma patient undergoing cervical spine CT and/or MRI examination Radiology department setting	Non- trauma patient and all other patients undergoing other radiological examination Non-radiology department	The research question is targeted towards cervical spine injuries. Hence inclusion of other body parts would be inappropriate To ensure that the examinations is carried out at the specific and appropriate setting.
All age group and sexes	None	To include a broader population for the study because spinal injuries affect all age and sex groups

relevant followed by abstracts, and full text screening. In addition, the senior investigator (TNA), reviewed the screening decisions for consistent application of the predetermined criteria at all stages of the screening exercise.

To ensure a consistent critical appraisal of the relevant studies, an adapted version of the Centre for Evidence Based Medicine's Diagnostic critical appraisal tool³⁸ was employed to evaluate the studies (see [supplementary Table S1](#)) to reduce the risk of bias from both study selection, inclusion, and assessment. Any differences in quality assessment ratings were discussed and consensus opinion was achieved among the research team. Of note, the aggregate quality ranking and critiquing exercises were not a part of the article exclusion criteria.³⁹ For data extraction, this included the completion of a tabular template with fields to capture the study methods, aims and outcomes (the findings and conclusions drawn) from all the included studies.

A thematic analysis approach⁴⁰ was deemed appropriate to explore the extracted data and integrate the findings from the included articles. The consideration of a thematic analysis strategy for synthesising the results became paramount due to the constraints with the other types of synthesis approaches in relation to the nature of the findings. Additionally, the thematic data synthesis approach provides a simplified yet robust approach for consistent synthesis of evidence obtained from all the included articles.^{41–43}

Table 2
PICO framework.

PICO	Elements relating to the research questions
Population	Trauma patients with cervical spine injuries
Intervention	Use of MRI imaging modality
Comparison	Computed Tomography scanning
Outcome	Impact on diagnostic assessment of trauma patients

Table 3
Search terms and phrases employed for the literature search.

Keywords	Synonyms
Trauma patients	Injured patients
Spinal injuries	Vertebral injuries, cervical spine injuries
MRI	MRI Scans, 'Magnetic Resonance Imaging'
CT scan	CAT scan, 'Computed Tomography'
Search Phrases Employed	
MRI OR "MRI scans" OR "Magnetic Resonance Imaging"	
AND	
"CT scan" OR "Computed Tomography"	
"Trauma patients" OR "injured patients"	
AND	
"Spinal injuries" OR "vertebral injuries" "cervical injuries"	

The findings were then integrated to generate summary outcomes using textual narratives and categorised into themes.

Results

[Fig. 1](#) details the results of the article selection process using an adapted PRISMA chart. Briefly, the search yielded 248 articles after the removal of duplicates from the following records: AMED = 110; CINAHL = 488; DelphiS = 1502; EMBASE = 126; MEDLINE = 301. Manual searches and review of the bibliography list of relevant articles yielded (n = 13). Fifteen articles met the final inclusion criteria including the key elements of the PICO framework. All the included articles scored highly on the critiquing assessment and were conducted to the required ethical standards. Of note, blinding was not conducted and/or reported in over 50% of the included studies (see [supplementary Table S1](#)). The final articles included were heterogeneous in nature, however, all addressed the key elements of the PICO framework as required.

Various themes and subthemes were identified in the findings of the included studies. The identification of emergent themes was based on the frequency of their occurrence across the included studies ([Table 4](#)). These themes were then amalgamated and led to the development of four major themes namely: *Theme 1 - Mechanism of injury*; *Theme 2 - Type of patient*; *Theme 3 - Injuries detected on MRI*; *Theme 4 - Significance of injuries detected on MRI*. These themes were used to direct the focus of the discussion.

Discussion

The overall value of MRI in the cervical spine imaging series of trauma patients is discussed according to the themes obtained from our analyses. The predominant findings indicate that MRI investigations may still be necessary following a normal CT scan in suspected CSI in line with the clinician's discretion, even, when there is evidence of gross motor function preservation.

Mechanism of injury

The mechanism of injury that prompts the use of MRI examination for trauma patients was reviewed. Nine studies attributed the major cause and highest contributing mechanism of injury to road traffic accidents.^{44–52} Three studies^{53–55} however identified falls, predominantly Ground Level Falls (GLF) as the major cause of the mechanism of injury predisposing patients to the need for identifying salient injuries on MRI that were not found on CT scans. One study⁵⁶ was not specific in the mechanism of injury associated with these scans. It may be assumed that this study covered all forms of

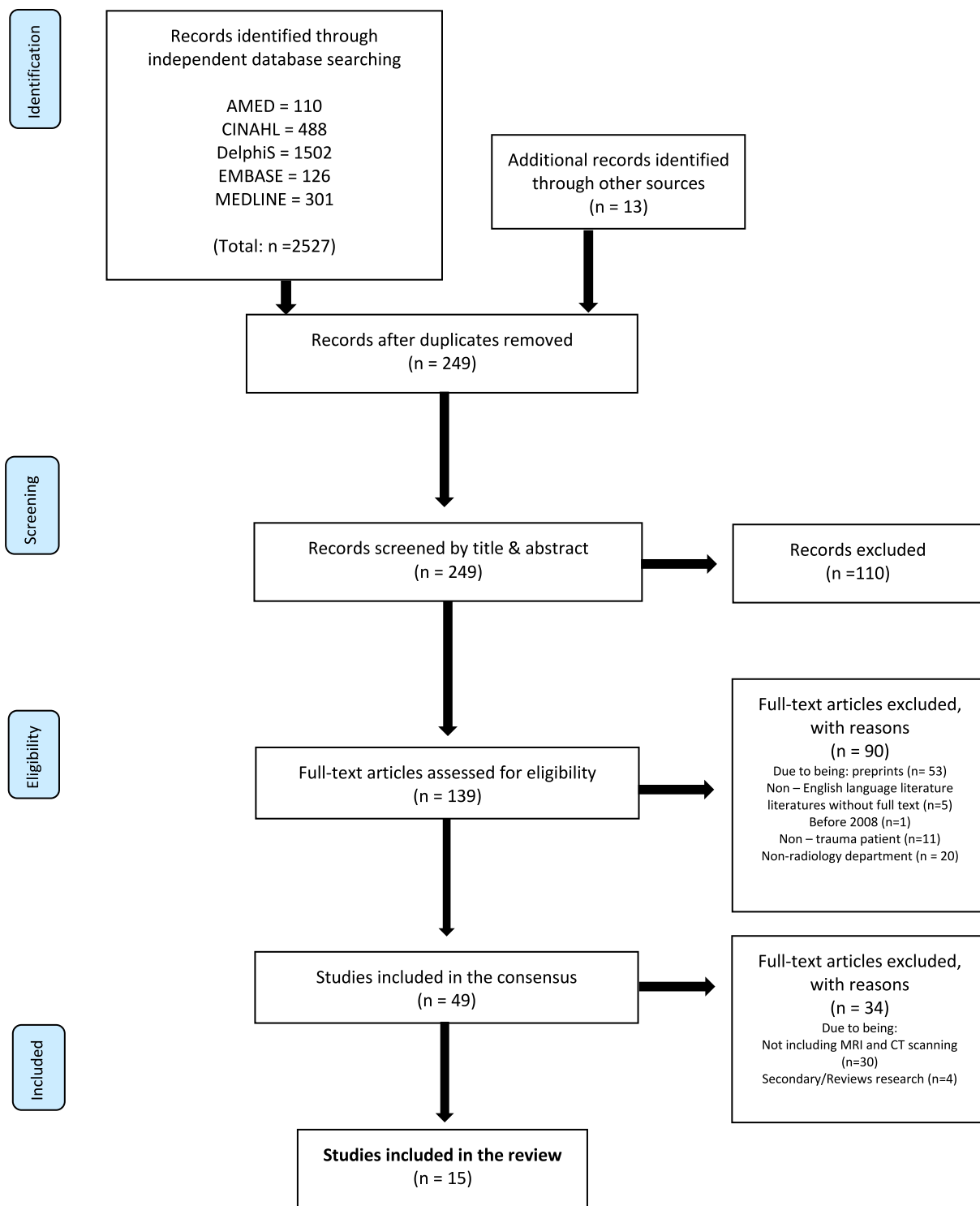


Figure 1. PRISMA Flow Diagram illustrating the search and screening process.

mechanisms that required CT and MRI scans. Lau et al.⁴⁵ also found that in milder forms of these mechanistic injuries, there is the potential to identify MRI findings that are not seen on CT scan images. This shows that while the obvious high impact mechanism of injury like road traffic accidents and falls from heights gives a signal of a potential need for further assessment with MRI when CT scan findings are normal, the less obvious mechanism of injuries like assaults

and sports may still require the need to conduct a further assessment with MRI even when there is a normal CT scan finding and clinical examination. Nevertheless, some authors^{28,29} opined that, there may not be the need for an MRI following a normal CT scan especially, when gross motor function remains intact. This is debatable as normal CT does not necessarily imply the absence of neuroanatomical destruction secondary to the trauma.^{28,29}

Table 4

Summary of extracted data and themes developed from the included literature.

No.	Reference, Country of study and Journal	Title	Methods			Aim of Study	Outcomes		Emergent Themes
			Study Setting	Study Design	Population & Sample size		Main findings & Conclusions	Strengths & Limitations	
1	Boruah et al., 2021 India Cureus	Added Value of Three-Plane Multi-echo Fast Field Echo MRI Sequence in the Evaluation of Acute Spinal Trauma Using Sensitivity: A Prospective Study.	Trauma center at a medical college	Prospective study	48 patients of acute spinal trauma comprising 36 males and 12 females of mean ages 38.71 years undergoing MRI scan	To evaluate the diagnostic efficacies of three-plane mFFE MRI sequences along with the conventional sequences in acute spinal trauma patients using sensitivity	Application of three- plane mFFE sequences detects more spinal cord hemorrhages and vertebral fractures with better visibility score as compared to the single sagittal plane mFFE and STIR sequence.	Three-plane mFFE sequences give better/higher visibility score of spinal soft tissue bony pathologies. No statistically significant difference was noted. Three-plane mFFE sequence was more time consuming A larger prospective study to confirm maybe needed.	1. Mechanism of injury 2. Type of patient 3. Type of injuries detected on MRI 4. Neurologic improvement of patient in relation to time of injury, 5. time of admission and scan time
2	Culhane, Parr and Mercier, 2022 USA BMC Emergency Medicine	Accuracy of CT evaluation for cervical spine clearance in the ground level fall population - a retrospective cohort study.	Level 1 trauma center at a single university hospital institution	Retrospective cohort study	3520 Ground Level Fall (GFL) trauma patients of mean ages 72.2years with 2588 undergoing CT for cervical spine (CS) clearance.	To analyse whether CT scan alone can rule out unstable injury in GLF with lower force mechanism of injury	In the GLF population, CT scan alone rules out unstable CS injury with high but not perfect NPV. The combination of absence of acute CT findings and acute neurologic deficit rules out unstable CS injury with 100% NPV A small portion had traumatic abnormalities on MRI. Further study is needed to identify criteria to determine when CS MRI should be performed in older patients with GLF	The registry included only patients with ISS >0 rather than all patients with GLF. CS injuries may be over-represented in the cohort study versus one that includes GLF patients with completely negative work-up. Limitations associated with a retrospective study methodology was experienced The Gilbert methodologic guidelines for medical review was followed to limit the introduction of bias. Study with small sample size limits generalizability of findings. Indications for cervical spine MRI were not defined and not consistently recorded in the	1. Type of patient 2. Type of cervical spine injury 3. Injury severity score
3	Cushing, Holmes and Tyler, 2021 USA Western Journal of Emergency Medicine	Cervical Spine Injuries in Older Patients with Falls Found on Magnetic Resonance Imaging After Computed Tomography.	Level 1 trauma center of an urban academic institution	Retrospective study	87 GLF patients going for MRI cervical spine after CT showed no evidence of an acute injury.	To determine the rate of traumatic abnormalities on cervical spine MRI after a normal cervical spine CT in older patients with GLF	A small portion had traumatic abnormalities on MRI. Further study is needed to identify criteria to determine when CS MRI should be performed in older patients with GLF	The Gilbert methodologic guidelines for medical review was followed to limit the introduction of bias. Study with small sample size limits generalizability of findings. Indications for cervical spine MRI were not defined and not consistently recorded in the	1. Type of patient 2. Patients' length of ED stay 3. Injuries detected on MRI

(continued on next page)

Table 4 (continued)

No.	Reference, Country of study and Journal	Title	Methods			Aim of Study	Outcomes		Emergent Themes
			Study Setting	Study Design	Population & Sample size		Main findings & Conclusions	Strengths & Limitations	
4	Fisher et al., 2013 USA The American Journal of Surgery	Is magnetic resonance imaging in addition to a computed tomographic scan necessary to identify clinically significant cervical spine injuries in obtunded blunt trauma patients?	Level 1 academic trauma center at university hospital.	Retrospective study	277 blunt trauma patients undergoing CT and MRI. 195 males and 82 females with mean age of 35.2 years.	To determine whether MRI is useful as an adjuvant imaging modality to more safely clear the cervical spine	CT scan alone is inadequate to rule out cervical spine injury Numbers needed to be screened with MRI to detect one clinically significant injury found to be 21 is significant.	records. Patients with similar mechanisms and ages did not all proceed with advanced imaging of the cervical spine, considering some of these patients may have had MRI injuries if imaged. The use of low ISS score to suggest the absence of other substantial injuries may have led to a missed diagnosis, even though no distracting injuries were specifically identified in this review Difference in the definition of clinical significance varies from study to study and between individual surgeons creates uncertainties Late presentation of injury may affect this cohort due to the prospective nature of the study.	1. Mechanism of injury 2. Time of MRI scan 3. Clinical significance of missed injuries
5	Fotakopoulos, Brotis and Fountas, 2022 Greece Cureus	Magnetic Resonance Imaging in Cervical Spine Trauma: More than Soft Tissue Illustration.	Trauma center	Case study	60 years old man who underwent CT C-spine and MRI after conservative management	To hypothesize that an MRI is essential in cervical spine injuries with a clinical and radiological mismatch To stress the importance of a specialized trauma protocol for such cases aiming to remove potential artefacts.	An anatomic abnormality in a C-spine study could appear as a traumatic fracture/subluxation and lead to a misdiagnosis. It is important to exclude artefacts as a source of normal variants and abnormal blood vessels of the cervical spine. CT is generally	The single case study methodology of this study makes it difficult for generalisability of the findings Radiologists and neurosurgeons must acquire adequate training in order to be wary of normal variants, anatomical abnormalities and structures that often imitate	1. Clinical presentation of patient 2. Type of injuries identified on MRI

6	Gargas et al., 2013 USA Journal of Trauma and Acute Care Surgery	An analysis of cervical spine magnetic resonance imaging finding after normal computed tomographic imaging findings in pediatric trauma patients: Ten-year experience of a level I pediatric trauma center.	Level 1 pediatric trauma center	Retrospective study	173 pediatric trauma patients with normal cervical spine CT scan and subsequently had cervical spine MRI. 115 males and 58 females of mean age 10.1 years	To determine the frequency of abnormal MRI findings after previously normal CT scan results	indicated in cervical trauma for bon visualisation whereas MRI is reserved for imaging of soft tissue lesions. However, MRI may frequently differentiate an active fracture from a dormant variant. MRI should be considered in cases with clinical and radiological mismatch. MRI of the cervical spine is not superior to helical CT scan with sagittal or coronal reconstruction of the spine in detecting unstable spine injuries High resolution CT scan may allow for earlier clearance in places where MRI is not available.	pathologies when it comes to a cervical spine study. The retrospective nature of the study is a limitation	1. Mechanism of injury 2. Type of patients assessed 3. Type of injuries detected on MRI 4. Clinical significance of injuries detected on MRI
7	Khanna et al., 2012 USA Journal of Trauma and Acute Care Surgery	The value of cervical magnetic resonance imaging in the evaluation of the obtunded or comatose patient with cervical trauma, no other abnormal neurological findings, and a normal cervical computed tomography	Level 1 trauma center of a medical center	Retrospective study	150 obtunded and comatose patients with negative CT results and underwent MRI; 101 males, 49 females and mean age of 36 years	Evaluating the two-conflicting hypothesis between CT and MRI; MRI of cervical spine adds no value to the evaluation of patients with a normal CT and MRI is the gold standard for clearing cervical spine in a clinically suspicious blunt trauma patient	The use of MRI in the setting of cervical clearance protocol adds little in the determination of stability of the cervical spine in the presence of a negative CT	The retrospective design of the study is a limitation.	1. Mechanism of injury 2. Availability of MRI scan 3. Time to MRI scan 4. Types of injuries detected by MRI 5. Clinical significance of injury
8	Lau et al., 2017 Singapore European Spine Journal	The utility of magnetic resonance imaging in addition to computed tomography scans in the evaluation of cervical spine injuries: a study of obtunded blunt trauma patients	Intensive Care Unit of an Emergency Medicine Department	Retrospective study	63 blunt trauma and obtunded patients who underwent Cervical spine CT and MRI scanning; 56 males, 7 females with a mean age of 42.3years	To determine and predict if computed Tomography (CT) alone can be performed without risk of oversight of substantial injuries found at follow-up MRI	Presence of MRI – specific injuries findings CT scan picked up most of the severe cervical spine injuries that would prompt an MRI follow-up scan regardless	Possibility of interval change between time of CT and MRI scans Unavailability of exact time interval between injury and MRI may impact the MRI findings	1. Mechanism of injury 2. Type of patient 3. Time of follow up MRI scan 4. Identification of injuries by MRI 5. Clearance of spine 6. Clinical significance of injuries detected by MRI

(continued on next page)

Table 4 (continued)

No.	Reference, Country of study and Journal	Title	Methods			Aim of Study	Outcomes		Emergent Themes
			Study Setting	Study Design	Population & Sample size		Main findings & Conclusions	Strengths & Limitations	
9	Maung et al., 2017 USA Journal of Trauma and Acute Surgery	Cervical spine MRI in patients with negative CT: A prospective, multicenter study of the Research Consortium of New England Centers for Trauma (ReCONNECT)	8 level I and II trauma centers part of ReCONNECT	Prospective multicenter observational study	667 blunt trauma patients from the 8 centers	To determine the rates of abnormal MRI after a negative CT scan results	MRI identified additional injuries in 23.6% of patients despite normal cervical spine CT Clinical significance of injuries identified on MRI is unclear Consensus between trauma team and spine surgery required to define which injury need treatment and acceptable rate of missed injuries.	Different centers may have different threshold for ordering MRI which prevents standardization Decision for MRI requested at the discretion of the trauma teams makes it had for a fair decision making. Study is specific to a group of patients which may not be representative of all trauma patients	1. Mechanism of injury 2. Type of patients 3. Time to MRI scan 4. Types of abnormalities found on MRI 5. Clinical significance of injuries
10	McCallum et al., 2017 Canada Trauma Journal	64-Slice CT compared to MRI to clear cervical spine injury in high-risk GCS<14 blunt trauma patient admitted to the ICU	Intensive care unit of a level 1 trauma center	Retrospective Observational study	44 blunt trauma patients with GCS <14, negative 64 – slice CT scan results and underwent follow up MRI; 34 males and 10 females with a median age of 35 years	To determine whether a negative CT-scan alone is sufficient to clear cervical spine injury	Missed injuries were detected on MRI of negative CT scan MRI findings were clinically significant injuries A combination of CT and MRI may be sufficient to clear clinically significant injuries.	High Acuity Retrospective nature with a small sample size Selection bias of only high-risk patients may have increased the clinically significant injury rate limiting generalizability	1. Type of patient 2. Clearance of cervical spine 3. Clinical impact of MRI 4. Clinical significance of missed injuries
11	Schoenwaelder, Maclaurin and Varma, 2009 Australia Injury Journal	Assessing potential spinal injury in the intubated multi-trauma patient: does MRI add value?	Intensive Care Unit of a level trauma center	Retrospective study	55 trauma patients with normal CT scan underwent MRI. 76 males, 24 females with 37.5%	To determine the role of MRI in intubated multi trauma patients with normal CT in excluding unstable ligamentous injury to cervical spine.	CT can exclude unstable injury using a 64- slice multidetector imaging with multiplanar capabilities with more confidence at a follow – up cervical spine MRI imaging.	Retrospective analysis of a relatively small sample size. Use of a single – slice helical image acquisition and resultant limited image quality is a limitation considering the widespread use of multidetector volumetric scanning.	1. Mechanism of injury 2. Type of patient 3. Type of injury detected 4. Clearance of spine 5. Rate of easiness with the use of MRI 6. Clinical significance of injuries
12	Sutherland et al., 2021 USA Annals of Medicine and Surgery	Utilization of computerized tomography and magnetic resonance imaging for diagnosis of traumatic C-Spine injuries at a level 1 trauma centre: A	Trauma and Surgical care unit of a Regional medical center	Retrospective cohort study	805 patients that underwent CT and MRI of the C-spine for various traumatic injury and presentation with a total of 305 females, 500 males	To investigate the utilisation of CT and MRI imaging in traumatic C-spine clearance and associated outcomes in patients undergoing	Need to support the utilization of CT and MRI in conjunction to detect both bony and soft tissue C-spine pathologies in traumatic injured patients.	Uniqueness of the study in that it directly stratifies traumatic injuries by cervical injury level as well as differing types of soft tissue injuries by utilising	1. Type of patient 2. Injuries detected on MRI 3. Injuries detected on CT 4. Clearance of cervical spine

		retrospective Cohort analysis.			and mean age of 42 years	both imaging modalities		radiological data from the TC in relation to patient outcomes. This has allowed for the demonstration of the predictive values of both CT and MRI with respect to different and specific traumatic injuries, allowing a greater clinical context for the findings. Limitations of a retrospective study methodology is associated with the study. Findings from the study are subject to limitations associated with the databases including a minimal degree of human error in accurate entry of patient data into the trauma registry. Unavailability of data prevented the assessment of impact of C-collar placement and other variables analysed on the long- term functional status or disability of patients who survived their injuries.	
13	Xin and Lei, 2022 China Contrast Media and Molecular Imaging	Diagnostic Value of Magnetic Resonance Imaging Scan, Multi-slice Spiral Computed Tomography Three-Dimensional Reconstruction Combined with Plain Film X-Ray in Spinal Injuries	Author's Affiliated Hospital Center	Retrospective study	100 patients with spinal injuries that received an MRI scan, multi-slice CT scan and plain film xray including 68 males and 32 females of mean age 49.41 years	Explore the diagnostic value of MRI, Multi-slice CT combined with plain film x-ray of spinal injuries.	MRI can reveal bonemarrow injury, ligament injury, soft tissue injury and nerve root injury that cannot be visualised on x-ray plain films. Multi-slice CT 3D reconstruction can clearly demonstrate the 3D relationship of spinal fracture displacement,	The retrospective nature of the study is a limitation.	1. Type of patient 2. Type of injuries detected 3. Clinical significance of injuries on CT and MRI

(continued on next page)

Table 4 (continued)

No.	Reference, Country of study and Journal	Title	Methods			Aim of Study	Outcomes		Emergent Themes
			Study Setting	Study Design	Population & Sample size		Main findings & Conclusions	Strengths & Limitations	
14	Martínez-Pérez et al., 2017 Spain World Neurosurgery	MRI Prognostication Factors in the Setting of Cervical Spinal Cord Injury Secondary to Trauma	Community Hospital Setting	Retrospective study	Eighty-six patients (68 males and 18 females) with mean age of 49 years.	To determine radiologic findings related to neurologic prognosis in patients after incomplete acute traumatic cervical spinal cord injury, regardless of initial neurologic examination results.	fracture line course, and spinal injury. MRI and Multi-slice CT can be used to observe the spinal injury comprehensively, which is conducive to reducing the disability rate and mortality rate of patients with spinal injuries. Early MRI has an intrinsic prognostic value. MRI can reveal bonemarrow injury, ligament injury, soft tissue injury and nerve root injury that	The retrospective nature of the study is a limitation.	1. Type of patient 2. Type of injuries detected 3. Clinical significance of injuries on MRI
15	Gruenewald et al., 2023 15 Heliyon	Injury patterns of the spine following blunt trauma: A per-segment analysis of spinal structures and their detection rates in CT and MRI	Trauma center	Retrospective study	216 patients (152 male and 64 female) with a mean age of 42.8 years (range, 4–85 years)	To provide a detailed analysis of injury patterns of the spine following blunt trauma and establish the role of supplementary MRI by evaluating discrepancies in the detection rates of damaged structures in CT and MRI.	In patients that sustained blunt spinal trauma, supplementary MRI of the cervical spine should routinely be performed to detect injuries that require surgical treatment. Novel information derived from MRI changed clinical management to surgical intervention in 2.4% by revealing unstable injuries to the cervical spine that were not detected in the previous CT examination	The retrospective nature of the study is a limitation	1. Mechanism of injury 2. MRI is Supplementary 3. Types of injuries detected by MRI Clinical

Type of patient

All the studies highlighted the type of patients that underwent MRI examination.^{44–52} Four of the studies^{45,48–50} reported that obtunded blunt trauma patients may require MRI after a normal CT scan for further evaluation of the anatomy of neurological relevance. Considering the definition of ‘obtunded’ which refers to being ‘less conscious or alert,’⁵⁷ it is important to acknowledge that a neurological deficit may not be fully investigated using a CT scan due to its low sensitivity in such situations. Therefore, the need for an MRI to detect any potential neurological injury is warranted. Most of the studies involved adults in the age range of 35–75 years, however, Gargas et al.⁴⁷ focused on the pediatric population. Fisher et al.⁴⁵ also included a mixed range of population in their study, covering adults, children less than 12 years old and children between 12 and 18 years old.

Depending on the severity of injuries, there may be the need to undertake CT instead of MRI for patients with additional injuries such as fractured limbs with immobilisations that impede assessment.⁵⁸ The type of patients that were identified in the studies had significant life-threatening physiological parameters which included the Glasgow Coma Scale (GCS) of less than 14, intubated patients and polytrauma patients.^{59,60} In this small cohort, there may be a need to assess using MRI in the event of a normal CT scan. Of note, most of the included studies^{28,29,32} reported no significant care alterations following MRI scans after normal CT findings in these patients.

Injuries detected on MRI

MRI can detect tendons, nerves, and ligamentous injury effectively.^{20,24} Ligamentous injuries of varied severity at different locations were detected by all the studies when MRI was performed.^{44,52} Other injuries reported by the studies included epidural and subdural hematoma. Besides, MRI frequently discerns an acute fracture from a chronic fracture, and thus, is often indicated in cases of clinico-radiological mismatch between clinical presentations and other imaging.⁴⁶ For example, evidence suggests there are possibilities of confusing vertebral fractures with motional artifacts, abnormal fistulous tracts, and even normal vascular variations.⁴⁶ Nonetheless some studies^{49,51,53} however, reported injuries using MRI that were previously not captured using CT and this include a presentation of bone oedema without fracture.^{49,51,56} Of note, bone marrow oedema and periosteal reaction are mostly non-specific findings which may characterise a fracture when using MRI. Steigelman and colleagues⁵⁹ similarly identified anatomical deficits on MRI which were missed on CT scans, these were mostly ligamentous injuries.^{49,50}

Schoenwaelder, Maclaurin and Varma⁵¹ are of the view that a multidetector imaging CT scanner with superior spatial resolution is more effective at detecting ligamentous injury than a single – slice helical CT scanner. Thus, with the emergence and increasing availability of advanced CT technology, such as photon counting and dual-energy CT, there could be a potentially comparable CSI detection sensitivity and specificity to MRI. Identifying salient injuries using specially optimised sequences (across various magnetic strengths) as a further diagnostic imaging approach may improve patient care. Of note, future studies may explore these diagnostic metrics across these modalities to guide clinical decision making.

Significance of injuries detected on MRI

Most of the studies reported the significance of injuries detected on MRI in terms of the interventions undertaken after MRI results, clearance of the spine and clinical management of the patients.^{44–52}

Whereas, McCallum et al.⁵⁰ reports that CT scan alone cannot be used to clinically clear CSI, and thus, MRI may be required if there was any clinical indication to warrant further investigation. Sliker, Mirvis and Shanmuganathan⁶¹ have also drawn out some restrictions with the use of MRI which includes the consideration of the presence of metallic devices, foreign bodies and some immobilisation and support equipment which may be incompatible with MRI. These concerns need to be considered especially in the case of TCSI where patients often report to facilities with some of these devices. Other studies,^{50,56} have also cited that MRI gives low specificity in the upper cervical spine region and a low sensitivity in the posterior cervical spine section, hence introducing some limitations in its ability to completely rule out CSI.

Some studies (see Table 4) highlighted that a high percentage ($\geq 74\%$) of CSI patients who had CT scans were cleared and did not require any interventions undertaken on them even after the MRI follow-ups. This is consistent with the findings of Khanna et al.⁴⁸ and Cushing, Holmes and Tyler⁵⁴ stating that MRI added little value in the determination of stability of the spine. Similarly, Culhane, Parr and Mercier⁵³ conclude that relying on acute CT findings and physical examination for acute neurologic deficits rules out unstable CSI with 100% negative predictive value, hence showing little significance of MRI in such instances. Some interventions were undertaken after the MRI results which included cervical collar usage, operative management, and surgical interventions^{45,47,48,54,55} but these were carried out in just a few of the patients with findings on MRI. It may be argued that some of the required surgical interventions following MRI, although rare, may be life changing. Of note, most patients suspected of CSI will receive these interventions even without MRI examination. Most studies,^{44–52} agreed that overall, there was no significant alteration in the clinical management of the patients irrespective of the MRI findings. This conclusion agrees with that of Tomycz et al.³² where 21.1% ($n = 38/180$) of patients had acute TCSI on MRI, however, detailed clinical report indicated that none of these patients had a missed unstable injury and no patient required surgery or developed evidence of delayed instability. These MRI findings were therefore deemed not significant to warrant a change in the patient treatment pathway. The findings of this review suggest a mixed opinion on the value of MRI in the diagnostic clinical decision pathways for the evaluation of TCSI. The decision whether to undertake MRI following a CT or projection radiography however lies with the clinician and this stems from guidelines and decision rules that are considered best practice linked to the type of patient (child or adult), the clinical presentation and the type of injury, availability of the imaging resource and the findings from CT and plain film.

Limitations

Our study has some limitations that need to be highlighted including consideration for only studies published in English. However, the geographic locations and the heterogeneity reported in the included studies represent different clinical settings and populations, respectively, and thus, allows for better generalisation of the findings. The data obtained did not allow for a meta-analysis due to the heterogeneity of the methodological designs and the disparity of the extracted information from the included studies.

Recommendations

In the evaluation of TCSI, the use of high-resolution CT is highly recommended for assessment and clearance of the cervical spine.^{47,49–54} Of note, the combination of a high-resolution CT technology with symmetric motor functions assessment^{50,53} and the use of MRI in the evaluation of cervical spine in some selected trauma patients (especially those with impaired neurological

deficits) will be supported if it is available.^{40,45,46} This, however, needs to be carefully considered in light of the clinical benefit to the patient and patient safety to undergo either of the two examinations or both.

It can be argued that given the complications of prolonged cervical immobilisation^{60,62} and limitations that are posed with the use of MRI in blunt obtunded trauma patients,⁶¹ opting for a high-resolution CT scanning is preferred. This argument may not be sustained because current MRI sequences are optimised to safely scan certain implants and immobilisation aids under certain conditions.

Secondly, due to the associated problems in terms of difficulty in accessibility and availability of MRI for certain geographical areas,²⁷ resources could be channelled into upgrading existing CT technologies with high-resolution image acquisition features.

Current clinical practice is more leaning toward the use of MRI as a confirmatory tool following normal findings of a CT scan of the cervical spine in trauma patients; especially following unreliable physical examinations.^{63–65} Although, this practice may highlight additional abnormalities, they mostly do not influence an alteration in the clinical care and management of TCSI patients. More importantly, from the myriad of evidence included in this study, it is our considered view that MRI holds value in TCSI interventional scenarios associated with neurological impairments and/or inconclusive physical clinical examination. However, where necessary and available, careful considerations must be given to the clinical benefits of using MRI⁶⁴ and the legal implications of missing life-threatening damages rather than just the cost and convenience.

Conclusion

MRI holds intrinsic prognostic value and principally useful in a small cohort of TCSI patients especially those with expressive neurologic abnormalities with normal CT presentations. Our findings indicate that MRI may be very valuable in some situations for the evaluation of TCSI, however, its usage must be cautiously considered on a case-by-case basis in light of additional clinical benefit, patient safety and resource availability following a normal CT scan or in conjunction with CT or projection radiography where appropriate. Future research to provide a global consensus and framework for the diagnostic imaging pathway for the management of TCSI is crucial.

Conflict of interest statement

All authors have no conflicts of interests to declare. Of note, TNA is a member of the editorial board but was blinded to the decision-making process.

Appendix A. Supplementary data

Supplementary data to this article can be found online at <https://doi.org/10.1016/j.radi.2024.04.017>.

References

- Buschmann C, Gahr P, Tsokos M, Ertel W, Fakler J. Clinical diagnosis versus autopsy findings in polytrauma fatalities. *Scand J Trauma Resuscitation Emerg Med* 2010;**18**(1):55.
- Kleber C, Giesecke M, Tsokos M, Haas N, Schaser K, Stefan P, et al. Overall distribution of trauma-related deaths in Berlin 2010: advancement or stagnation of German trauma management? *World J Surg* 2012;**36**(9):2125–30.
- Grossman M, Reilly P, Gillett T, Gillett D. National survey of the incidence of cervical spine injury and approach to cervical spine clearance in U.S. Trauma centres. *J Trauma Inj Infect Crit Care* 1999;**47**(4):684.
- Marshall L, Knowlton S, Garfin S, Klauber M, Eisenberg H, Kopaniky D, et al. Deterioration following spinal cord injury: a multicenter study. *J Neurosurg* 1987;**66**(3):400–4.
- Dunham C, Brocker B, Collier B, Gemmel D. Risks associated with magnetic resonance imaging and cervical collar in comatose, blunt trauma patients with negative comprehensive cervical spine computed tomography and no apparent spinal deficit. *Crit Care* 2008;**12**(4):R89.
- Pfeifer R, Pape H. Missed injuries in trauma patients: a literature review. *Patient Saf Surg* 2008;**2**(1):20.
- Ackland H, Cameron P. Cervical spine: assessment following trauma. *Australian family physician* 2012;**41**(4):196–201.
- NICE guidelines [NG41] on Spinal injury: assessment and initial management. Published on February 2016. <https://www.nice.org.uk/guidance/ng41>. Accessed on 15/September/2023.
- Guidelines for the initial management and assessment of spinal injury. British Trauma Society, 2002. *Injury* 2003;**34**:405–25.
- Linder F, Mani K, Juhlin C, Eklöf H. Routine whole-body CT of high energy trauma patients leads to excessive radiation exposure. *Scand J Trauma Resuscitation Emerg Med* 2016;**24**(1).
- Department of Health, Western Australia. Diagnostic imaging pathways-cervical spine injury. <https://www.imagingpathways.health.wa.gov.au/incudes/dipmenu/summary.html> [Accessed 19 August 2023].
- Ajani AE, Cooper DJ, Scheinkestel CD, Laidlaw J, Tuxen DV. Optimal assessment of cervical spine trauma in critically ill patients: a prospective evaluation. *Anaesth Intensive Care* 1998;**26**:487–91.
- Stähler A, Eck J, Penning R, Milz SP, Bartl R, Resnick D, et al. Cervical spine: postmortem assessment of accident injuries-comparison of radiographic, MRI imaging, anatomic and pathologic findings. *Radiology* 2001;**221**:340–6.
- Diaz JJ Jr, Gillman C, Morris Jr AJ, May AK, Carrillo YM, Guy J. Are five-view plain films of the cervical spine unreliable? A prospective evaluation in blunt trauma patients with altered mental status. *J Trauma* 2003;**55**:658–63.
- Davis JW, Phreaner DL, Hoyt DB, Mackersie RC. The etiology of missed cervical spine injuries. *J Trauma* 1993;**34**:342–6.
- Diaz JJ Jr, Aulino JM, Collier B, Roman C, May AK, Miller RS, et al. The early work-up for isolated ligamentous injury of the cervical spine: does computed tomography scan have a role? *J Trauma* 2005;**59**:879–903.
- Goldberg A, Kershah S. Advances in imaging of vertebral and spinal cord injury. *The Journal of Spinal Cord Medicine* 2010;**33**(2):105–16.
- Gebauer G, Osterman M, Harrop J, Vaccaro A. Spinal cord injury resulting from injury missed on CT scan: the danger of relying on CT alone for collar removal. *Clin Orthop Relat Res* 2012;**470**(6):1652–7.
- Como J, Thompson M, Anderson J, Shah R, Claridge J, Yowler C, et al. Is Magnetic Resonance Imaging essential in clearing the cervical spine in obtunded patients with blunt trauma? *J Trauma Inj Infect Crit Care* 2007;**63**(3):544–9.
- Castillo M. Current use of MR imaging in spinal trauma. *Emerg Radiol* 1999;**6**(3):121–3.
- Corr P, Govender S. The role of magnetic resonance imaging on spinal trauma. *Clin Radiol* 1999;**54**(10):629–35.
- Sledge J, Allred D, Hyman J. Use of magnetic resonance imaging in evaluating injuries to the pediatric thoracolumbar spine. *Journal of Pediatric Orthopedics* 2001;**21**(3):288–93.
- Gold M. Magnetic resonance imaging of spinal emergencies. *Top Magn Reson Imag* 2015;**24**(6):325–30.
- Utz M, Khan S, O'Connor D, Meyers S. MDCT and MRI evaluation of cervical spine trauma. *Insights into imaging* 2014;**5**(1):67–75.
- Hodgson R, O'Connor P, Grainger A. Tendon and ligament imaging. *The British Journal of Radiology* 2012;**85**(1016):1157–72.
- Harris M, Sethi R. The initial assessment and management of the multiple trauma patient with an associated spine injury. *Spine* 2006;**31**(suppl11):S9–15.
- Pierrson A, Gorleku P. Assessment of availability, accessibility, and affordability of magnetic resonance imaging in Ghana. *Radiography* 2017;**23**(4):e75–9.
- James IA, Moukalled A, Yu E, Tulman DB, Bergese SD, Jones CD, et al. A systematic review of the need for MRI for the clearance of cervical spine injury in obtunded blunt trauma patients after normal cervical spine CT. *J Emergencies, Trauma, Shock* 2014;**7**(4):251–5.
- Muchow R, Resnick D, Abdel M, Munoz A, Anderson P. Magnetic resonance imaging (MRI) in the clearance of the cervical spine in blunt trauma: a meta-analysis. *J Trauma Inj Infect Crit Care* 2008;**64**(1):179–89.
- Antevil J, Sise M, Sack D, Kidder B, Hopper A, Brown C. Spiral computed tomography for the initial evaluation of spine trauma: a new standard of care? *J Trauma Inj Infect Crit Care* 2006;**61**(2):382–7.
- Stelfox H, Velmahos G, Gettings E, Bigatello L, Schmidt U. Computed Tomography for early and safe discontinuation of cervical Spine immobilization in obtunded multiply injured Patients. *J Trauma Inj Infect Crit Care* 2007;**63**(3):630–6.
- Tomycz N, Chew B, Chang Y, Darby J, Gunn S, Nicholas D, et al. MRI is unnecessary to clear the cervical spine in obtunded/comatose trauma patients: the four-year experience of a level I trauma center. *J Trauma Inj Infect Crit Care* 2008;**64**(5):1258–63.
- Craxford S, Bayley E, Walsh M, Clamp J, Boszczyk B, Stokes O. Missed cervical spine injuries. *The Bone & Joint Journal* 2016;**98-B**(6):825–8.
- Platzer P, Jaundl M, Thalhammer G, Dittrich S, Wieland T, Vecsei V, et al. Clearing the cervical spine in critically injured patients: a comprehensive C-spine protocol to avoid unnecessary delays in diagnosis. *Eur Spine J* 2006;**15**(12):1801–10.
- Cumpston M, Li T, Page MJ, Chandler J, Welch VA, Higgins JP, et al. Updated guidance for trusted systematic reviews: a new edition of the Cochrane

- Handbook for Systematic Reviews of Interventions. *Cochrane Database Syst Rev* 2019;**2019**(10).
36. Page MJ, McKenzie JE, Bossuyt PM, Boutron I, Hoffmann TC, Mulrow CD, et al. The PRISMA 2020 statement: an updated guideline for reporting systematic reviews. *Int J Surg* 2021;**88**:105906.
 37. Schardt C, Adams MB, Owens T, Keitz S, Fontelo P. Utilization of the PICO framework to improve searching PubMed for clinical questions. *BMC Med Inf Decis Making* 2007;**7**:16. <https://doi.org/10.1186/1472-6947-7-16>.
 38. Center for Evidence Based Medicine. *Diagnostic critical appraisal worksheet (online) university of oxford*. 2014. <https://www.cebm.net/2014/06/critical-appraisal/>. [Accessed 25 June 2018].
 39. Moher D, Liberati A, Tetzlaff J, Altman D. Preferred reporting Items for systematic reviews and meta-analyses: the PRISMA statement. *PLoS Med* 2009;**6**(7):e1000097.
 40. Aveyard H. *Doing a literature review in Health and social care: a practical guide*. Berkshire, England: Open University Press; 2014.
 41. Hong QN, Pluye P, Bujold M, Wassef M. Convergent and sequential synthesis designs: implications for conducting and reporting systematic reviews of qualitative and quantitative evidence. *Syst Rev* 2017;**6**:61. <https://doi.org/10.1186/s13643-017-0454-2>.
 42. Noyes J, Booth A, Moore G, Flemming K, Tunçalp Ö, Shakibazadeh E. Synthesising quantitative and qualitative evidence to inform guidelines on complex interventions: clarifying the purposes, designs and outlining some methods. *BMJ Glob Health* 2019;**4**:e000893. <https://doi.org/10.1136/bmjgh-2018-000893>.
 43. Braun V, Clarke V. Conceptual and design thinking for thematic analysis. *Qualitative Psychology* 2022;**9**(1):3–26. <https://doi.org/10.1037/qap0000196>.
 44. Boruah DK, Hazarika K, Borah KK, Ahmed H, Sharma BK. Added value of three-plane multiecho fast field echo MRI sequence in the evaluation of acute spinal trauma using sensitivity: a prospective study. *Cureus* 2021;**13**(4):e14694. <https://doi.org/10.7759/cureus.14694>.
 45. Fisher B, Cowles S, Matulich J, Evanson B, Vega D, Dissanaik S. Is magnetic resonance imaging in addition to a computed tomographic scan necessary to identify clinically significant cervical spine injuries in obtunded blunt trauma patients? *Am J Surg* 2013;**206**(6):987–94.
 46. Fotakopoulos G, Brotis AG, Fountas KN. Magnetic resonance imaging in cervical spine trauma: more than soft tissue illustration. *Cureus* 2022;**14**(1):e21493. <https://doi.org/10.7759/cureus.21493>.
 47. Gargas J, Yaszay B, Kruk P, Bastrom T, Shellington D, Khanna S. An analysis of cervical spine magnetic resonance imaging findings after normal computed tomographic imaging findings in pediatric trauma patients. *J Trauma Acute Care Surg* 2013;**74**(4):1102–7.
 48. Khanna P, Chau C, Dublin A, Kim K, Wisner D. The value of cervical magnetic resonance imaging in the evaluation of the obtunded or comatose patient with cervical trauma, no other abnormal neurological findings, and a normal cervical computed tomography. *J Trauma Acute Care Surg* 2012;**72**(3):699–702.
 49. Lau B, Hey H, Lau E, Nee P, Tan K, Tan W. The utility of magnetic resonance imaging in addition to computed tomography scans in the evaluation of cervical spine injuries: a study of obtunded blunt trauma patients. *Eur Spine J* 2017;**27**(5):1028–33.
 50. McCallum J, McLaughlin P, Hameed M, Kanji H. 64-Slice CT compared to MRI to clear cervical spine injury in high-risk GCS < 14 blunt trauma patients admitted to the ICU. *Trauma* 2017;**20**(1):38–45.
 51. Schoenwaelder M, Maclaurin W, Varma D. Assessing potential spinal injury in the intubated multitrauma patient: does MRI add value? *Injury* 2009;**40**:S13.
 52. Xin D, Lei L. Diagnostic value of magnetic resonance imaging scan, multislice spiral computed tomography three-dimensional reconstruction combined with plain film X-ray in spinal injuries. *Contrast Media Mol Imaging* 2022;**2022**:8998231. <https://doi.org/10.1155/2022/8998231>.
 53. Culhane J, Parr A, Mercier P. Accuracy of CT evaluation for cervical spine clearance in the ground level fall population - a retrospective cohort study. *BMC Emerg Med* 2022;**22**(1):106. <https://doi.org/10.1186/s12873-022-00657-x>.
 54. Cushing CH, Holmes JF, Tyler KR. Cervical spine injuries in older patients with falls found on magnetic resonance imaging after computed tomography. *West J Emerg Med* 2021;**22**(5):1190–5. <https://doi.org/10.5811/westjem.2021.5.51844>.
 55. Maung A, Johnson D, Barre K, Peponis T, Mesar T, Velmahos G, et al. Cervical spine MRI in patients with negative CT. *J Trauma Acute Care Surg* 2017;**82**(2):263–9.
 56. Sutherland M, Bourne M, McKenney M, Elkbuli A. Utilization of computerized tomography and magnetic resonance imaging for diagnosis of traumatic C-Spine injuries at a level 1 trauma center: a retrospective Cohort analysis. *Annals of medicine and surgery* 2021;**68**:102566. <https://doi.org/10.1016/j.amsu.2021.102566> (2012).
 57. Oxford English Dictionary (Online). *Obtunded*. 2018. Available at: <http://dictionary.oed.com>. [Accessed 20 September 2023].
 58. Bates LJ, Davey J, Watson B, King MJ, Armstrong K. Factors contributing to crashes among young drivers. *Sultan Qaboos University Medical Journal* 2014;**14**(3):e297–305.
 59. Steigelman M, Lopez P, Dent D, Myers J, Corneille M, Stewart R, et al. Screening cervical spine MRI after normal cervical spine CT scans in patients in whom cervical spine injury cannot be excluded by physical examination. *Am J Surg* 2008;**196**(6):857–63.
 60. Powers J, Daniels D, McGuire C, Hilbish C. The incidence of skin breakdown associated with use of cervical collars. *J Trauma Nurs* 2006;**13**(4):198–200.
 61. Sliker CW, Mirvis SE, Shanmuganathan K. Assessing cervical spine stability in obtunded blunt trauma patients: review of medical literature. *Radiology* 2005;**234**(3):733–9.
 62. Morris CGT, McCoy É. Clearing the cervical spine in unconscious polytrauma victims, balancing risks and effective screening. *Anesthesia* 2004;**59**(5):464–82.
 63. Powe C. Cervical spine clearance in the blunt trauma patient. *J Trauma Nurs* 2006;**13**(2):80–4.
 64. Martínez-Pérez R, Cepeda S, Paredes I, Alen JF, Lagares A. MRI prognostication factors in the setting of cervical spinal cord injury secondary to trauma. *World Neurosurg* 2017;**101**:623–32. <https://doi.org/10.1016/j.wneu.2017.02.034>.
 65. Gruenewald LD, Koch V, Eichler K, Bauer J, Gruber-Rouh T, Booz C, et al. Injury patterns of the spine following blunt trauma: a per-segment analysis of spinal structures and their detection rates in CT and MRI. *Heliyon* 2023;**9**(6):e17396. <https://doi.org/10.1016/j.heliyon.2023.e17396>.
 66. Barry ES, Merkebu J, Varpio L. State-of-the-art literature review methodology: a six-step approach for knowledge synthesis. *Perspect Med Educ* 2022;**11**(5):281–8. <https://doi.org/10.1007/s40037-022-00725-9>.
 67. Grant MJ, Booth A. A typology of reviews: an analysis of 14 review types and associated methodologies. *Health Inf Libr J* 2009;**26**(2):91–108. <https://doi.org/10.1111/j.1471-1842.2009.00848.x>.